

# **Violence: Recognition, Management, and Prevention**

## **A REVIEW OF 300 ATTEMPTED STRANGULATION CASES PART III: INJURIES IN FATAL CASES**

Dean A. Hawley, MD,\* George E. McClane, MD,† and Gael B. Strack, JD‡

\*Department of Pathology and Laboratory Medicine, Indiana University School of Medicine, Indianapolis, Indiana;

†Department of Community Medicine at Stanford Medical School, Stanford, California; ‡Office of the San Diego City Attorney, Criminal Division, San Diego, California

Reprint Address: Dean A. Hawley, MD, Department of Pathology and Laboratory Medicine, Indiana University School of Medicine, 635 Barnhill, Med Sci Bldg Rm 157, Indianapolis, IN 46202-5120

□ **Abstract**—A review of 300 cases of alleged strangulation assault, submitted for misdemeanor prosecution by the San Diego City Attorney's Office, led to a search for medical evidence that would be useful to prosecute these cases (see Strack et al. in this issue of the Journal). The injuries identified in these non-fatal cases are similar to injuries found in fatal domestic violence strangulation assaults. This article reviews the injuries recognizable at autopsy in cases of strangulation in domestic violence victims. © 2001 Elsevier Science Inc.

□ **Keywords**—strangulation; domestic violence; forensic pathology; autopsy; larynx; violence

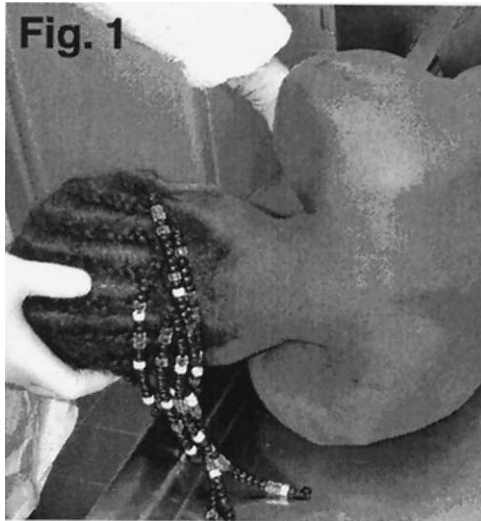
### **INTRODUCTION**

Gonzales, in 1933, relying on European references from the 19th century, published an early report on strangulation (1). The process of strangulation, whether by hand (manual), or by ligature, results in blunt force injury of the tissues of the neck. The pattern of these injuries allows us to recognize strangulation as a unique mechanism, and to distinguish strangulation from other blunt injuries including hanging, traumatic blows to the neck, and artifacts of decomposition (2–8).

It is no coincidence that the best medical evidence of

strangulation is derived from post mortem examination (autopsy) of the body, but even in living survivors of strangulation assaults it may be possible to recognize a pattern of injury distinctive for strangulation. An autopsy affords the ability to examine all of the tissues of the neck, superficial and deep, and track the force vector that produced the injuries. In living people, the assessment of the patient is limited to superficial examination of the skin, and two-dimensional shadows by radiography (9,10). Oftentimes, even in fatal cases, there is no external evidence of injury. While patterned abrasions and contusions of the skin of the anterior neck are typical of strangulations cases, some cases have no externally evident injury whatsoever. The injuries that may occur include patterned contusions and abrasions caused by fingernails, finger touch pads, ligatures, or clothing. These injuries are prone to change over time, with the healing process. Injuries not at all apparent on the day of death may actually become visible by the next day, as the skin begins to dry and become more transparent.

Much medical research has been published on the findings of strangulation, owing to a no-longer promoted practice by police agencies wherein “choke holds” were taught and practiced as a way for officers to subdue suspects (11). The summary experience with choking for control of suspects—also called the “carotid restraint

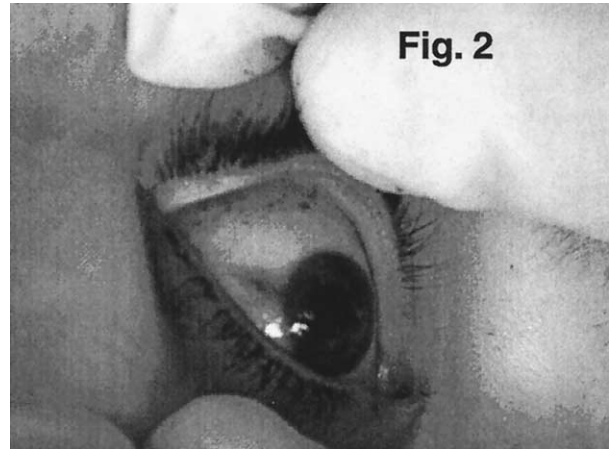


**Figure 1.** Shoulder injuries may occur with forearm strangulation, also called the “carotid restraint hold.” With the assailant behind the victim, strangulation by a forearm around the neck can leave abrasion or contusion at the tops of the shoulders, related to positioning of the assailant’s elbow and fingers.

hold,” “shime waza,” or “the sleeper hold”—is that death can ensue without the intent of the officer, and without leaving external marks on the body. When this maneuver is performed—whether for police custody control or for intentional assault—the body may show contusion or abrasion on the top or back of the shoulders, related to the position of the assailant’s elbow and fingers (Figure 1).

In addition to the blunt force injuries of the neck, strangulation produces evidence of asphyxiation, recognized as pinpoint hemorrhages (petechiae) in the skin, conjunctiva of the eyes, and deep internal organs (12,13). Petechiae are non-specific findings that can develop from any cause of asphyxia including strangulation, hanging, drowning, sudden infant death syndrome, aspiration of gastric contents, profound depressant drug intoxication, and some natural diseases. The presence of petechiae does not prove strangulation, and the absence of petechiae does not disprove strangulation (14). In addition to petechiae, one may also (rarely) find interstitial free air in the lung or mediastinum (15). Petechiae may be very difficult to recognize in the skin of darkly pigmented people. The conjunctiva may show petechiae (Figure 2). At autopsy, a common place to find petechiae is the undersurface of the scalp (Figure 3). The internal mucosal lining of the larynx may show petechiae (Figure 4), and might be potentially demonstrable by fiberoptic laryngoscopy in the Emergency Department (ED).


Fingernail marks are superficially incised curvilinear abrasions, occurring singly or in sets. In rare cases, all four fingers will mark the skin in a single pattern. Fin-



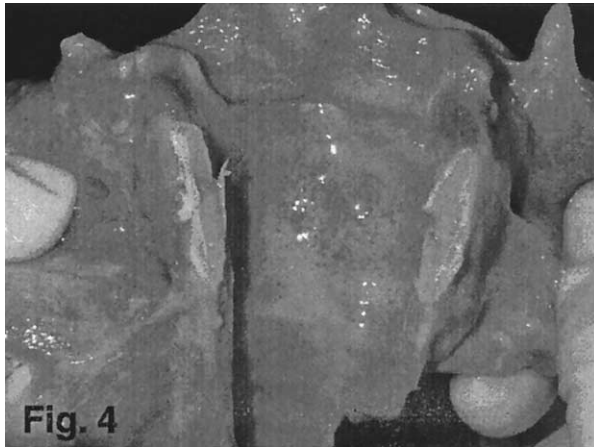
**Figure 2.** Petechiae may be found in the conjunctiva of the eye. In darkly pigmented skin, petechiae may not be visible. Examination of the eyes and the mucosa of the lower lip may reveal petechiae.

gnail marks are rarely associated with the assailant’s hands, but commonly associated with the victim’s own fingers, as she struggles to pry the assailant’s grasp off her neck (Figures 5 and 6). Finger touch pad contusions are caused by the assailant’s grasp. The thumb generates more pressure than the other fingers, so singular thumb impression contusions are found more often than contusions showing the complete hand grasp. Ligature abrasions follow a predictable pattern of horizontal circumscription about the neck; distinguishable from the marks left by suicidal hanging, where a suspension point causes the ligature furrow to rise toward one ear.

Domestic violence strangulation can be fatal without any external evidence of injury on the skin of the neck.

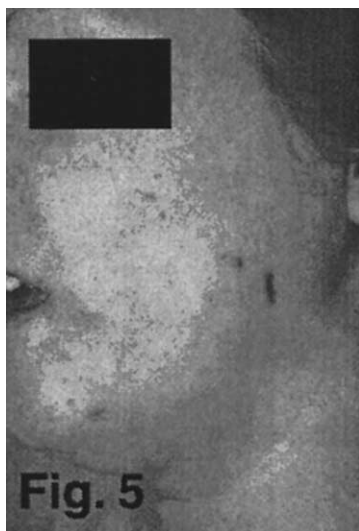

**Figure 3.** Petechiae appear on the undersurface of the scalp at autopsy. At autopsy, the scalp is reflected forward over the face, to reveal the undersurface, showing petechiae.

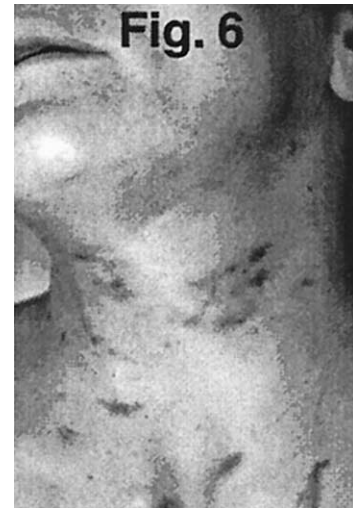

**Figure 4.** Petechiae may appear on the mucosal surface of the larynx, below the vocal cords. Petechiae may be found in the internal organs in a variety of conditions, and may appear in the larynx in strangulation.

Police homicide investigators are frequently posed a difficult problem, wherein the victim of a domestic violence strangulation is found dead, often reported by the assailant, with a vague history of substance abuse or depression, and no injuries evident on the body. If no suspicion of domestic violence is developed during the scene investigation, there may be little or no suspicion of criminal harm when the victim presents for autopsy examination. Without external evidence of skin injury, an autopsy will be conducted to rule out drug overdose, and the injury of strangulation will not be found until the



**Figure 5.** Curvilinear abrasions may be produced by the victim's own fingernails. The victim, while struggling to release her assailant's stranglehold, may injure herself by scraping her fingernails into the skin of the face or throat.



**Figure 6.** Fingernail marks may appear as patterned abrasions on the skin. The struggling victim may produce long patterned scratch marks on her own face or neck while trying to pry her assailant's hands or ligature off her neck.

neck dissection is carried out, ordinarily at the end of the case. Therefore, photographs and trace evidence collections will not have been made from the undisturbed body, and the prosecutor will be left without essential evidence.

Careful death scene investigation is essential. The scene investigation may be useful in identifying strangulation assaults, based on blood spatter and ligatures (16). Rarely, the latent fingerprints of the assailant may be recovered from the skin of the victim's neck (17,18). Of research interest, it may be possible to actually recover the assailant's skin cells from the victim's injured neck, and by DNA-typing, prove the identity of the recovered cells are from the assailant (19,20).

Ultimately, a medical opinion of strangulation as the mechanism of neck injury will be based on a complete examination of the patient's neck, either at autopsy or by radiography, to detect superficial and deep injuries fitting a pattern that supports the diagnosis. A commonly cited injury is fracture of the hyoid bone, actually only found in a minority (at most one-third) of all fatal strangulations (21–27). One must keep in mind that the seriousness of the internal injury may take a few hours to be appreciated, and delayed death has been reported (28,29).

Autopsy examination of the neck includes complete dissection with removal of the larynx including the hyoid bone, and preferably with the tongue attached. The superficial and deep musculature must be individually examined for contusion hemorrhage. The laryngeal skeleton is then exposed to examine for fracture. Finally, the cervical spine is opened and examined for injury.

There is considerable misunderstanding about the neck injury in hanging, including the notion that radical displaced fractures occur. Fracture of cervical vertebrae C2 and C3 (the “hangman’s fracture”), alleged to occur in judicial hanging, relates to the force applied by dropping the body some distance, against a ligature applied from the side of the neck (30). In suicidal hanging, as opposed to judicial hanging, there is rarely a drop of the body. Most suicidal hangings are accomplished while standing or kneeling. A common misconception is that there will be fractures or some sort of internal neck injury in people who hang themselves. In fact, in suicidal hanging there is scarcely ever any internal evidence of neck injury at all (5,7,10). Suicidal hanging is usually effected with very little force. It is painless, and can be accomplished even when lying down in bed. External injury, including the dramatic “rope burns” or ligature abrasion, only occurs after the body has been suspended for several hours after death. If the ligature is released at the moment of death, there will be no mark on the skin. After the body has hung suspended by the ligature for a few hours, a very dramatic furrow and ligature abrasion will develop post-mortem.

Immediate death from hanging or strangulation can progress from one of four mechanisms:

1. Cardiac dysrhythmia may be provoked by pressure on the carotid artery nerve ganglion (carotid body reflex) causing cardiac arrest.
2. Pressure obstruction of the carotid arteries prevents blood flow to the brain.
3. Pressure on the jugular veins prevents venous blood return from the brain, gradually backing up blood in the brain resulting in unconsciousness, depressed respiration, and asphyxia.
4. Pressure obstruction of the larynx cuts off air flow to the lungs, producing asphyxia.

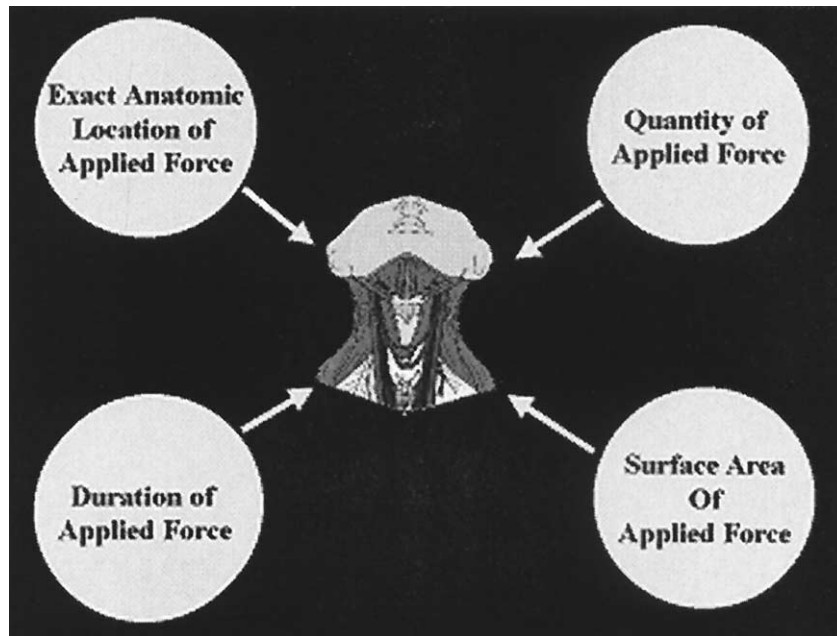
The first mechanism (carotid body reflex) is very uncommon. The reflex cardiac dysrhythmia can be reproducibly demonstrated in humans, but force must be applied over a very localized and specific anatomic area. The second mechanism (carotid arterial obstruction) is also very uncommon in suicidal hangings, but may be more frequent in homicidal strangulations. Quite a bit of pressure is required to obstruct arterial flow in the carotids, and that amount of force typically would be associated with obvious soft tissue injury locally in the neck. The third mechanism (jugular venous obstruction) is probably the usual route for death by suicidal hanging. Slight pressure fully or at least partially obstructs venous return bilaterally in the internal and external jugular veins, gradually causing passive congestion of blood in the vessels within the brain. Note that this mechanism is different from

surgical ligation or surgical sacrifice of one of the four jugular veins, typical of radical neck surgery. Partially obstructing return in all four veins diminishes oxygen delivery to the brain, eventually resulting in loss of consciousness. The type of pressure required is slight, but prolonged. Unconsciousness probably doesn’t occur for several minutes, but the overall process is completely painless.

In cases of suicidal hanging, eventually the individual becomes unconscious, then the fourth mechanism (laryngeal obstruction) takes over. With the person unconscious, the full weight of the suspended part of the body falls against the ligature, creating enough pressure to restrict air flow through the trachea. Then, irreversible asphyxiation follows in just a few minutes. In strangulation cases, and some suicidal hangings where the individual is “saved” before death, there may be a prolonged period of survival with obvious brain damage, followed by death. This delay is the effect of loss of blood flow to the brain, with partial asphyxiation of the brain. A decrease in blood flow to the brain will produce a pathologic change called anoxic encephalopathy. Brain cells are not all equally sensitive to loss of blood flow. Some cells die soon, while others survive for days and eventually succumb to the delayed effect of oxygen deprivation. Nerve cell death may be patchy in the brain. The nerve cells of the hippocampus and dentate nucleus, and Purkinje cells of the cerebellum, are more susceptible to anoxia than cortical nerve and glial cells. Fatal anoxic encephalopathy results in clinical “brain death” where the body functions of the heart and internal organs can be maintained by medical life support, but all hope of meaningful recovery is lost. Complications may include persistent vegetative coma, cerebral edema (brain swelling), and herniation of the brain. For patients who do recover consciousness, lifelong brain damage may be observed.

Quantitating the actual forces applied to the neck is not a meaningful exercise. The amount of force required to compress the jugular veins is less than the force to compress the carotids, and that in turn is less than the force required to constrict the airway. However, absolute values—measured as foot-pounds of force—vary tremendously from one person to the next depending on development of neck musculature, and the surface area for the application of force. If the force were applied over a very narrow surface area—a clothesline ligature as opposed to a broad belt, for example—then much less force would be necessary. Four variables are working simultaneously, as shown in Figure 7.

For the same amount of pressure, if you decrease the surface area, or increase the duration of the force, you increase the likelihood that the force will be fatal. Further, if even a small force is applied in just the right



**Figure 7. Four variables working simultaneously in strangulation. There are four variables that interact in making a strangulation assault a fatal injury.**

anatomic area, the force may obviate the normal anatomic protections of the neck musculature and skeleton. A small woman can easily strangle a large man.

Medical resuscitation, and organ procurement procedures, work against the pathologist's ability to detect fatal homicidal neck injury (12). An oxygen mask can leave abrasions on the mouth and nasal bridge. During resuscitation, an airway tube is placed into the mouth or nose, and inserted into the esophagus or trachea, to establish a path through which air can be forced under pressure to the lungs. The usual airway device is an oral endotracheal tube, but many varieties of hardware exist. The skill of the rescue staff, and the size and rigidity of the victim, dictate how much injury occurs during this intubation procedure. Traumatic intubations result in internal injuries of the deep musculature of the larynx, often completely mimicking the injuries of strangulation. Ulceration of the larynx may develop from pressure produced by the inflatable cuff on the tube. The mechanical ventilation can produce barotrauma in the lungs, with air dissecting up to the skin of the neck. In cases where the rescue staff is unable to intubate the patient, they may attempt a surgical cricothyrotomy or tracheostomy procedure to establish an airway. This may completely obliterate all signs of manual strangulation. Further, IV needles are sometimes placed into the jugular veins, leaving tracks of hemorrhage that can obscure physical injuries. If resuscitation is successful, the patient may linger on mechanical ventilation for hours or days, resulting in healing of soft tissue injuries in the

neck that would have been recognizable if examined earlier. Toxicology is essentially meaningless in patients who survive a few days in the hospital, so disproving, beyond a reasonable doubt, a defense theory that the asphyxial death was caused by overdose of prescribed or abused drugs becomes impossible (3).

In some communities, organ procurement procedures are routinely performed, regardless of the circumstances of death. A dissection for heart donation can totally obliterate all evidence of injury by manual strangulation. Donation of corneas will obscure observation of petechia in the eyes. The prosecutor is then dependent on the organ procurement team to recognize subtle injuries before they are obscured by the procedure. Few organ procurement technicians or physicians have any experience testifying in murder trials. In the autopsy investigation of strangulation in domestic assault cases, every injury on the body becomes significant. Contusions of the chest wall, abdomen, and extremities become valuable evidence to establish a pattern of abuse. Like child abuse cases, the autopsy strives to illuminate a big picture, not just focus singularly on the neck examination. Each and every bruise and scrape is important. These peripheral injuries can be jeopardized by organ and tissue donation procedures. Organ and tissue procurement may be possible in suspected domestic violence homicide cases, but should be approached with caution by the medical teams, because of the risk of losing important evidence.

## REFERENCES

1. Gonzales TA. Manual strangulation. *Arch Pathol* 1933;15:55–65.
2. Kelly M. Trauma to the neck and larynx [Review]. *Crna* 1997;8:22–30.
3. Missliwetz J, Vycudilik W. Homicide by strangling or dumping with postmortem injuries after heroin poisoning? *Am J Forens Med Pathol* 1997;18:211–4.
4. Denic N, Huyer DW, Sinal SH, Lantz PE, Smith CR, Silver MM. Cockroach: the omnivorous scavenger. Potential misinterpretation of postmortem injuries. *Am J Forens Med Pathol* 1997;18:177–80.
5. Samarasekera A, Cooke C. The pathology of hanging deaths in Western Australia. *Pathology* 1996;28:334–8.
6. Ortman C, Fechner G. [Unusual findings in death by hanging—reconstruction of capacity for action]. *Archiv fur Kriminologie* 1996;197:104–10. [German].
7. Howell MA, Guly HR. Near hanging presenting to an accident and emergency department. *J Acc Emerg Med* 1996;13:135–6.
8. Maxeiner H. “Hidden” laryngeal injuries in homicidal strangulation: how to detect and interpret these findings. *J Forens Sci* 1998;43:784–91.
9. Scaglione M, Romano L, Grassi R, Pinto F, Calderazzi A, Pieri L. [Diagnostic approach to acute laryngeal trauma: role of computerized tomography]. *Radiologia Medica* 1997;93:67–70. [Italian].
10. Poquet E, Dibiane A, Jourdain C, el-Amine M, Jacob A, Escure MN. [Blunt injury of the larynx by hanging. X-ray computed tomographic aspect]. *Journal de Radiologie* 1995;76:107–9. [French].
11. Koiwai EK. Deaths allegedly caused by the use of “choke holds” (Shime-Waza). *J Forens Sci* 1987;32:419–32.
12. Hood I, Ryan D, Spitz WU. Resuscitation and petechiae. *Am J Forens Med Pathol* 1988;9:35–7.
13. Rao VJ, Wetli CV. The forensic significance of conjunctival petechiae. *Am J Forens Med Pathol* 1988;9:32–4.
14. Ely SF, Hirsch CS. Asphyxial deaths and petechiae: a review. *J Forens Sci* 2000;45:1274–7.
15. Soto-Campos JG, Garcia-Diaz E, Elias T. [Pulmonary edema and mediastinal emphysema caused by strangulation (letter; comment)]. *Archivos de Bronconeumologia*. 1995;31:488. [Spanish].
16. Cartwright AJ. Degrees of violence and blood spattering associated with manual and ligature strangulation: a retrospective study. *Medicine, Science and the Law* 1995;35:294–302.
17. Hammer HJ. [Methods for detection of latent fingerprints from human skin]. *Forens Sci Intl* 1980;16:35–41. [German].
18. Graham D. Some technical aspects of the demonstration and visualization of fingerprints on human skin. *J Forens Sci* 1969;14:1–12.
19. Grellner W, Benecke M. The quantitative alteration of the DNA content in strangulation marks is an artifact. *Forens Sci Intl* 1997;89:15–20.
20. Wiegand P, Kleiber M. DNA typing of epithelial cells after strangulation. *Intl J Legal Med* 1997;110:181–3.
21. Pollanen MS, Bulger B, Chiasson DA. The location of hyoid fractures in strangulation revealed by xeroradiography. *J Forens Sci* 1995;40:303–5.
22. Khokhlov VD. [The mechanisms of the formation of injuries to the hyoid bone and laryngeal and tracheal cartilages in compression of the neck]. *Sudebno-Meditsinskaia Ekspertiza* 1996;39:13–6. [Russian].
23. Patel F. Strangulation injuries in children [letter: comment]. *J Trauma* 1996;41:171.
24. Hanigan WC, Aldag J, Sabo RA, Rose J, Aaland M. Strangulation injuries in children. Part 2: cerebrovascular hemodynamics. *J Trauma* 1996;40:73–7.
25. Sabo RA, Hanigan WC, Flessner K, Rose J, Aaland M. Strangulation injuries in children. Part 1. clinical analysis [see comments]. *J Trauma* 1996;40:68–72.
26. Pollanen MS, Chiasson DA. Fracture of the hyoid bone in strangulation: comparison of fractured and unfractured hyoids from victims of strangulation. *J Forens Sci* 1996;41:110–3.
27. Podporinova EE. [Forensic medical expertise in manual strangulations]. *Sudebno-Meditsinskaia Ekspertiza* 1996;39:6–9. [Russian].
28. Anscombe AM, Knight BH. Case report: delayed death after pressure on the neck: possible causal mechanisms and implications for mode of death in manual strangulation discussed. *Forens Sci Intl* 1996;78:193–7.
29. Malek AM, Higashida RT, Phatouros CC, Halback VV. A strangled wife. *Lancet* 1999;353(9161):1324.
30. Laurence J. *The history of capital punishment*. New Jersey: Citadel Press;1960:47–51.