

# **Violence: Recognition, Management, and Prevention**

## **A REVIEW OF 300 ATTEMPTED STRANGULATION CASES PART II: CLINICAL EVALUATION OF THE SURVIVING VICTIM**

George E. McClane, MD,† Gael B. Strack, JD,\* and Dean Hawley, MD‡

†Emergency Physician, Sharp Grossmont Hospital, San Diego, California, \*San Diego City Attorney's Office, San Diego, California; and Faculty, Department of Community Medicine, Stanford Medical School, Stanford, California; and ‡Department of Pathology and Laboratory Medicine, Indiana University School of Medicine, Indianapolis, Indiana

Reprint Address: George E. McClane, MD, Sharp Grossmont Medical Center, 5555 Grossmont Center Drive, San Diego, CA 91942

□ **Abstract**—Medical literature describing victims who survive strangulation is scant. The majority of articles on strangulation are found in the forensic literature, describing the post-mortem findings on autopsy. This article presents a suggested protocol for the evaluation and treatment of the surviving victim of strangulation, based upon a review of the available literature. It also corroborates the findings of Strack et al., in the study by the San Diego City Attorney's Office, described in Part I of this series. © 2001 Elsevier Science Inc.

□ **Keywords**—strangulation; manual strangulation; throttling; documentation; clinical guidelines; domestic violence; intimate partner violence

aspirating on an object, such as a piece of candy or a small toy (3). This distinction is legally important in criminal cases and the violent act should be addressed specifically as “strangulation.”

Ligature strangulation is strangulation with a cord-like object (also referred to as garroting), and may include anything from a telephone cord to articles of clothing (4,5). The general clinical sequence of a victim who is being strangled is one of severe pain, followed by unconsciousness, followed by brain death. The victim will lose consciousness by any one or a combination of the following: blocking of the carotid arteries, blocking of the jugular veins, or closing off the airway.

### **INTRODUCTION**

In exhaustive reviews of the literature on the subject of strangulation, it was soon discovered that it is important, if not critical, to clearly distinguish “strangulation” from “choking.” Strangulation, in the lay sense, is immediately associated with throttling, and is defined as “a form of asphyxia characterized by closure of the blood vessels or air passages of the neck as a result of external pressure on the neck” (1,2). However, the more ambiguous “choking” can refer to either the violent act of strangulation or

### **METHOD**

The literature on strangulation, describing physical findings in living victims as well as post-mortem findings, was reviewed. The review focused on the clinical approach to the strangled victim. Lycos on-line language translation was utilized for available foreign-language articles, including Russian and German. This review, with knowledge gained through clinical experience treating victims of strangulation, resulted in a suggested

protocol for evaluating the victims of strangulation who present to the Emergency Department (ED).

### EMERGENCY DEPARTMENT PRESENTATION AND PERSPECTIVES

The study by Strack et al. in this issue of JEM reveals that 150 of 300 (50%) of the victims who had been strangled and survived, had no visible markings to the neck and 35% of the victims had very minor injuries. In addition, most of these victims did not present to an ED for evaluation. Unfortunately, battered women who present to EDs with a broad range of physical complaints but who do not have obvious serious injuries frequently receive only a cursory history and physical examination (10–14).

Patients who do present to the ED and report being strangled are often under-evaluated and frequently dismissed as only being drunk, hysterical, or hyperventilating (6–9). Their description of the attempted strangulation is often viewed as an exaggerated claim and not addressed with a clinically appropriate work-up, unless visible markings (fingernail markings, erythema, ecchymoses, etc.) to the neck are apparent (15–17). The patient may be considered by the medical staff to be unreliable, or labeled as emotionally labile. Subsequently, other legitimate claims may be dismissed because of perceived “emotional instability.” If there is any evidence or admission of drug or alcohol use—even if the patient is not intoxicated—staff may be even more biased against her.

Other findings of strangulation such as the ocular findings of subconjunctival hemorrhages may be misdiagnosed as “pink eye” (see Figure 1a and b). Conditions of hoarseness or a “hot potato voice” (which occurs in up to 50% or more victims), may be attributed by medical personnel to the patient having screamed during an argument with her partner or even smoker’s cough, especially if these are true (18).

A “hyperventilating” patient actually may be symptomatic from any number of pathologic conditions secondary to the strangulation attempt. Aspiration pneumonia is a progressively worsening condition that may start off with relatively mild symptoms (19). If the patient had managed to fight vigorously during the strangulation, managing to gulp down air whenever she could pry off the chokehold, she may have inflated her stomach with air. This, mixed with terror, may have caused her to vomit, with subsequent aspiration either by gulping down a quick breath again, or by becoming progressively obtunded because of oxygen deprivation. Milder cases of pneumonia may also occur hours or days later (20). If the assailant completely closed off her airway, her attempt to

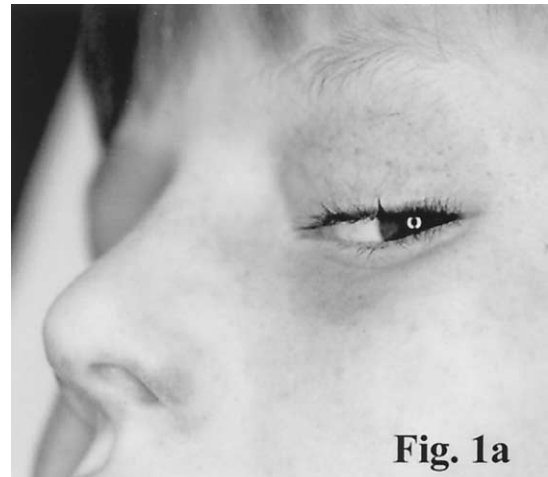

Fig. 1a

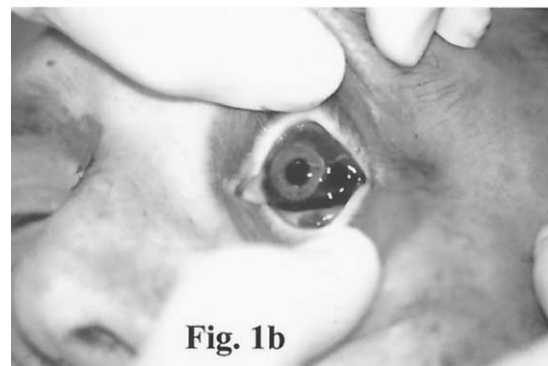


Fig. 1b

**Figure 1. Petechiae in the upper eyelid skin (a), and subconjunctival hemorrhage (b).**

breathe against a closed-glottis can result in pulmonary edema (21,22). Mislabeling such physical findings as “hyperventilation and histrionics” in an effort to rapidly “treat and street” the patient without getting an appropriate work-up is a serious disservice to survivors of intimate partner violence (IPV) who have been strangled. Progressively worsening pulmonary conditions may result in a fatal outcome—often after the patient has been discharged.

### VICTIM STREAM-OF-CONSCIOUSNESS DURING STRANGULATION

It is important to discern and document the mental and emotional status of these patients and their perceptions of what happened during the strangulation event. This is especially important in the medical record. Documentation of the patient’s emotional demeanor is especially useful and relevant for the courts if these cases go forward for prosecution.

Among the patients who are strangled to the point of

unconsciousness or near-syncope, many feel as though they will die. They have characteristically and consistently described four stages in their last few moments of alertness. These four stages of thought are:

Denial  
Realization  
Primal  
Resignation

### *Denial*

Patients describe an almost out-of-body experience, where frequently they will make such statements such as “I couldn’t believe that it was happening,” or “It was like I was watching it on TV.”

### *Realization*

The realization that they are being throttled quickly overcomes the denial stage.

### *Primal*

Realization yields to mammalian instincts. A vigorous struggle often ensues in a primal attempt to preserve airway and life.

### *Resignation*

Usually significantly outweighed and overpowered, these tiring victims—almost always female—resign themselves to the fact that “this is it—this is how I die.” Invariably, when asked what their final thoughts were before losing consciousness, these patients have wondered who would take care of their children in their absence.

## **BACKGROUND**

Only minimal pressure placed upon the neck is required to cause potentially serious injury—especially if the victim is compromised by intoxication or other pathologic conditions (23). Hawley et al., in this issue of JEM, review the forensic aspects of fatal strangulation and discuss in further detail the importance of surface area, duration of the force applied to the neck, and other factors that expand beyond simple pounds per square inch of applied force.

Medical literature, especially studies in Russia and Germany, supports that early and delayed mental status changes may occur because of temporary brain anoxia or Post-Traumatic Stress Disorder Syndrome (PTSD). These behavioral changes may be transient or permanent, depending upon mitigating factors (24,25).

Clinical experience supports the medical literature that describes behavioral changes in patients who have been strangled. Behavioral changes may manifest early as restlessness and combativeness because of temporary brain anoxia or a severe stress reaction, and subsequently resolve. Mental status changes also may be long-term, resulting in frank psychosis and amnesia.

Many of these patients present to the ED with an acute panic attack and may be hyperventilating. On further questioning, many patients may complain of sore throat and hoarseness accompanying the hyperventilation. In the study by Strack et al., 7% of the strangulation victims reported symptoms such as hyperventilation, memory loss, and uncontrollable shaking, symptoms that have all been well documented in the medical literature (31). Others will present in a detached state with a flat affect—even catatonic. Some patients will have complete recall of the event, despite concurrent intoxication with drugs or alcohol, while others may be entirely sober and yet have no memory of the event whatsoever. Unfortunately, with the latter patients, there may be a high suspicion among ED staff that the claim of strangulation, which may have been described by others present at the scene, is exaggerated, if to be believed at all. Yet a careful physical examination may reveal subtle findings, for example, petechiae in the conjunctivae, the scalp, or even the external ear canal, corroborating the history.

Finally, and perhaps most importantly, victims may have no visible injuries whatsoever, with relatively mild symptoms, and yet may die up to days or even several weeks later because of progressive, irreversible encephalopathy (26–31).

## **PROTOCOL FOR CARE OF SURVIVING VICTIMS OF STRANGULATION**

Apart from general supportive measures and observation, recommendations on the treatment of victims of strangulation in current and past medical literature are vague at best. No formal algorithms or protocols were found in the articles and texts reviewed. To set forth an initial set of printed guidelines, we propose the clinical options set forth in Table 1 to be considered in the management of these patients. These clinical monitoring devices, imaging studies, and procedures are listed from the readily available and least invasive, to the more comprehensive. These investigative tools are not intended to be applied

**Table 1. Clinical Evaluation Methods for Patients Who Have Been Strangled**

Pulse oximetry
Chest X-ray
Nasal X-ray
Soft tissue neck X-ray
Cervical spine X-rays
Computed axial tomography (CT) of the neck
Magnetic resonance imaging (MRI) of the neck
Carotid doppler ultrasound
Pharyngoscopy
Fiberoptic laryngobronchoscopy

in a strict linear manner per se. The more detailed imaging studies and invasive procedures should be employed when and where possible for patients with more significant findings, such as dyspnea, behavioral or neural status changes, or visible neck lesions.

*Pulse Oximetry:* A simple, non-invasive, fingertip transducer that measures a patient's oxygen saturation utilizing infra-red technology. The first step in evaluating a patient with mental status changes that may be secondary to hypoxemia.

*Chest X-Ray Study:* Rapid diagnosis of pulmonary edema, pneumonia, or aspiration.

*Nasal X-Ray Study:* Ancillary evaluation for the strangled patient presenting with hemoptysis (because of nasal fracture).

*Soft Tissue Neck X-ray Study:* For evaluation of subcutaneous (SC) emphysema within the soft tissues because of fractured larynx. May also demonstrate tracheal deviation because of edema or hematoma.

*Cervical Spine X-ray Study:* The lateral view may reveal a fractured hyoid bone.

*Axial Computed Tomography (CT) Scan:* For detailed cross-sectional evaluation of neck structures.

*Magnetic Resonance Imaging (MRI) Scan:* Comprehensive evaluation of soft tissues of the neck.

*Carotid Doppler Ultrasound:* Critical in patients with neurologic lateralizing signs (i.e., stroke).

*Pharyngoscopy:* Simple bedside maneuver that may reveal pharyngeal petechiae, edema, or other findings caused by strangulation.

*Fiberoptic Laryngobronchoscopy:* Vocal cord and tracheal evaluation in patients with dyspnea, dysphonia, aphonia, or odynophagia.

Patients who report having been strangled should be admitted. This allows for continuous monitoring of their airway, breathing, and circulation (ABC's), vital signs, and serial neurologic checks. In many patients, a social services consult will be appropriate, as many chronically battered patients suffer from profoundly poor self-esteem

and major depression. These women may experience overwhelming despair after the violent act of being strangled and may even exhibit suicidal ideation; suicide precautions in these patients are prudent. Any progressively worsening symptoms, such as odynophagia, hoarseness, neurologic changes, or dyspnea warrant admission with consults from Otolaryngology, Pulmonology, or Neurology. Clinical judgment should be used when patients' presentations are vague. Special care and an aggressive search for occult injury should be employed in the drug or alcohol-intoxicated patient with a history of strangulation. Patients who are in extremis in the field should be routed to a trauma center.

Of special concern is the patient who declines admission. In these cases, a social services consult definitely should be obtained, and care taken to explain to the patient the potential fatal consequences of possible occult underlying injuries. It should be carefully pointed out to the patient that numerous cases have been documented in the medical literature describing victims who had been strangled and lived—but have later died because of progressive causes. Admitting these patients also ensures that they are kept in a safe environment in the hospital, away from their batterers. Finally, important data and further research can be accomplished in this information-scarce area of the surviving victim of strangulation.

## CONCLUSION

Emergency Physicians must take seriously any patient who reports a history of recent strangulation injury. Special attention must be given to any patient who states she had a sense of impending death while being strangled. This may be a vital clue to possible occult underlying pathology. Asking the patient how she was strangled—one hand or two, use of a ligature, for how long, in what position, and when it occurred—can be helpful in the evaluation of possible underlying injury. Also, questions such as, "What did you see in his eyes while you were being strangled? What was he saying to you as you were being strangled? What did you think was going to happen?" may elicit detailed information from the patient. The patient's answers should be recorded in quotation marks. Such comments may not assist the initial clinical evaluation of the patient, but will be critically important when later introduced in court.

Ten percent of violent deaths each year in the United States are directly because of strangulation and many of these victims die without a single visible mark to the neck. Additionally, if these patients are victims of intimate partner violence (including same-sex relationships), care must be taken to provide them with information on shelters and other services. It is imperative that when

these patients are medically cleared, they be provided with information on community resources for victims of IPV. Patients who return to the same abuser probably will be strangled again, as abusers tend to perpetrate the same type of violence over and over, often with ever-increasing rage and worsening injury toward the victim. Unfortunately, a subsequent act of strangulation on the same patient-victim may result in a much more tragic fate.

## REFERENCES

- Line WS Jr, Stanley RB Jr, Choi JH. Strangulation: a full spectrum of blunt neck trauma. *Ann Otol Rhino Laryngo* 1985;94,6,1: 542–6.
- Iserson K. Strangulation: a review of ligature, manual and postural compression injuries. *Annotated Emerg Med* 1984;13(3):179–85.
- Wolf HB. Webster's New Collegiate Dictionary. G. C. Merriam Co.; 2001;196.
- Rupp JC. Suicidal Garroting and Manual Self-Strangulation. *J Forensic Sci* 1979;15(1).
- Hansch CF. Throat-skeleton fractured by strangulation. *A Rechtsmed* 1977;79(2):143–7. [German].
- Garimella R, Plichta SB, Houseman C. *J Women's Health Gend Based Med* 2000;9(4):405–11.
- Leserman J, Li Z, Drossman DA. *Psychol Med* 1998;28(2):417–25.
- Frank JB, Rodowski MF. *Emerg Med Clin North Am* 1999;17(3): 657–77.
- Elliott AJ, Pages KP, Russo J. *J Clin Psychiatry* 1996;57(12):567–71.
- Rodriguez MA, Bauer HM, McLoughlin E. *JAMA* 1999;282(5): 468–74.
- Warshaw C. *Acad Med* 1997;72(1 Suppl):S26–37.
- Campbell JC, Coben JH, McLoughlin E. *Acad Emerg Med* 2001; 8(2):131–8.
- Pittman PM. *Int J Qual Health Care* 1999;11(5):397–405.
- Bassuk EL, Melnick S, Browne A. *J Am Med Women's Assoc* 1998;53(2):57–64.
- Perper AJ, Sobel MN. Identification of fingernail markings in manual strangulation. *Am J Forensic Med Pathol* 1981;2(1):45–8.
- Starrs JE. Procedure in identifying fingernail imprint in human skin survives appellate review. *Am J Forensic Med Pathol* 1985;6(2): 171–3.
- Stanley RB Jr, Hanson DG. Types of injuries and interrelated conditions of victims and assailants in attempted and homicidal strangulation. *Forensic Sci Intl* 1981;18:101–23.
- Maxeiner H. Manual strangulation injuries of the larynx. *Arch Otolaryngol* 1983;109:344–7.
- Rothschild MA. Aspiration of gastric contents in hanging with typical position of the strangulation cord suspension. *Arch Kriminol* 1992;190(3–4):97–102. [German].
- Grellner W. The Value of various lung changes in death by strangulation. *Arch Kriminol* 1995;196(1–2):38–45. [German].
- Nasemann J. Animal Experiment Studies of Acute Emphysema caused by Strangulation. *Beitr Gerichtl Med* 1982;40:123–8. [German].
- Kita T, Furuya Y. Mechanisms of the Pulmonary Congestion in Ligature Strangulation. *Igaku Kenkyu* 1989;59(3):97–8. [Japanese].
- Furuya Y, Shintaku K, Kita T. Pulmonary tissues in strangulation. *Igaku Kenkyu* 1983;53(1):19–22. [Japanese].
- Luke JL, Reay DT, Eisele JW. Correlation of circumstances with pathological findings in asphyxial deaths by hanging: a prospective study of 61 cases from Seattle, WA. *J Forensic Sci JFSCA* 1985; 30(4):1140–7.
- Fedotov DD, Korsakova SS. Mental disorder in strangulation asphyxia. *Ah Nevropatol Psikhiatr Im* 1976. [Russian].
- Sabo RA, Hanigan WC, Flessner K. Strangulation injuries in children. *J Trauma: Injury, Infections & Critical Care* 1996;40(1): 68–72.
- Gerlach H. Late death after strangulation. *Deutsche Z Gesamte Gerichtl Med* 1966;58(1):50–4. [German].
- Crompton MR. Progressive multifocal leukoencephalopathy following(3)545–9.
- Hori A. Delayed post-anoxic encephalopathy after strangulation. *No To Hattatsu* 1998;30(6):529–34. [Japanese].
- Maxeiner H. Delayed death following strangulation. *Arch Kriminol* 1987;180(5–6):161–71. [German].
- Kubo S, Ogata M, Iwasaki M, Kitamura O. A case of hypoxic brain damage consequent to ligature strangulation. *Nippon Holgaku Zasshi* 1989;43(2):186–90I. [Japanese].
- Nathan F. On the absence of cutaneous lesions of the neck in cases of strangulation. *Minerva Medicol* 1967;87(6):299–302.
- Anscombe AM. Case report. Delayed death after pressure on the neck: possible causal mechanisms for mode of death in manual strangulation discussed. *Forensic Sci Int* 1996;78(3):193–7.
- Simpson RD Jr, Goodman JC, Rouah E, Caraway N, Baskin DS. Late neuropathological consequences of strangulation. *Resuscitations* 1987;15(3):171–85.
- James LL. Strangulation as a method of homicide. *Arch Path* 1967;83:64–70.